The American Journal of Sports Medicine
http://ajs.sagepub.com/

Hamstring Reinjuries Occur at the Same Location and Early After Return to Sport: A Descriptive Study of MRI-Confirmed Reinjuries

Arnlaug Wangensteen, Johannes L. Tol, Erik Witvrouw, Robbart Van Linschoten, Emad Almusa, Bruce Hamilton and Roald Bahr

Am J Sports Med 2016 44: 2112 originally published online May 16, 2016
DOI: 10.1177/0363546516646086

The online version of this article can be found at:
http://ajs.sagepub.com/content/44/8/2112

Published by:
SAGE
http://www.sagepublications.com

On behalf of:
American Orthopaedic Society for Sports Medicine
AOSSM

Additional services and information for *The American Journal of Sports Medicine* can be found at:

Email Alerts: http://ajs.sagepub.com/cgi/alerts

Subscriptions: http://ajs.sagepub.com/subscriptions

Reprints: http://www.sagepub.com/journalsReprints.nav

Permissions: http://www.sagepub.com/journalsPermissions.nav

>> Version of Record - Aug 1, 2016

OnlineFirst Version of Record - May 16, 2016

What is This?

Downloaded from ajs.sagepub.com at OHIO STATE UNIVERSITY LIBRARY on August 23, 2016

Hamstring Reinjuries Occur at the Same Location and Early After Return to Sport

A Descriptive Study of MRI-Confirmed Reinjuries

Arnlaug Wangensteen,*[†‡] PT, MSc, Johannes L. Tol,[†§] MD, PhD, Erik Witvrouw,[†‖] PT, PhD, Robbart Van Linschoten,[†] MD, PhD, Emad Almusa,[†] MD, Bruce Hamilton,[†¶] MD, and Roald Bahr,[†‡] MD, PhD
Investigation performed at Aspetar Orthopaedic and Sports Medicine Hospital, Doha, Qatar

Background: Despite relatively high reinjury rates after acute hamstring injuries, there is a lack of detailed knowledge about where and when hamstring reinjuries occur, and studies including imaging-confirmed reinjuries are scarce.

Purpose: To investigate the location, radiological severity, and timing of reinjuries on magnetic resonance imaging (MRI) compared with the index injury.

Study Design: Case series; Level of evidence, 4.

Methods: A MRI scan was obtained ≤5 days after an acute hamstring index injury in 180 athletes, and time to return to sport (RTS) was registered. Athletes with an MRI-confirmed reinjury in the same leg ≤365 days after RTS were included. Categorical grading and standardized MRI parameters of the index injury and reinjury were scored by a single radiologist (with excellent intra-observer reliability). To determine the location of the reinjury, axial and coronal views of the index injury and reinjury were directly compared on proton density–weighted fat-suppressed images.

Results: In the 19 athletes included with reinjury, 79% of these reinjuries occurred in the same location within the muscle as the index injury. The median time to RTS after the index injury was 19 days (range, 5-37 days; interquartile range [IQR], 15 days). The median time between the index injury and reinjury was 60 days (range, 20-316 days; IQR, 131 days) and the median time between RTS after the index injury and the reinjury was 24 days (range, 4-311 days; IQR, 140 days). More than 50% of reinjuries occurred within 25 days (4 weeks) after RTS from the index injury and 50% occurred within 50 days after the index injury. All reinjuries with more severe radiological grading occurred in the same location as the index injury.

Conclusion: The majority of the hamstring reinjuries occurred in the same location as the index injury, early after RTS and with a radiologically greater extent, suggesting incomplete biological and/or functional healing of the index injury. Specific exercise programs focusing on reinjury prevention initiated after RTS from the index injury are highly recommended.

Keywords: hamstring injury; reinjury; location; magnetic resonance imaging; return to sport

Reinjury rates after acute hamstring injuries are reported to range from 14% to 63% within the same playing season or up to 2 years after the initial injury.[11-14,23,44] Despite relatively high reinjury risk after hamstring injuries, there is a lack of exact knowledge about their severity, location, and timing. The reinjuries reported in previous studies were predominantly diagnosed clinically and were not confirmed by imaging. It has been suggested that a recurrent injury should be defined as trauma to the same location as the initial injury after return to sport (RTS) confirmed by magnetic resonance imaging (MRI) or sonography,[11] but studies including imaging-confirmed reinjuries are limited.

Silder[44] reported that in 3 reinjuries that were reimaged, the injury severity (measured on MRI as the craniocaudal length, cross-sectional area, and normalized T2 hyperintensity of injury) did not appear worse than the initial injury. MRI-confirmed hamstring reinjuries have been

*Address correspondence to Arnlaug Wangensteen, PT, MSc, Aspetar Orthopaedic and Sports Medicine Hospital, Sport City Street, PO Box 29222, Doha, Qatar (email: arnlaug.wangensteen@aspetar.com).

[†]Aspetar Orthopaedic and Sports Medicine Hospital, Doha, Qatar.

[‡]Oslo Sports Trauma Research Center, Department of Sports Medicine, Norwegian School of Sport Sciences, Oslo, Norway.

[§]Amsterdam Center for Evidence Based Medicine, Academic Medical Center, Amsterdam, the Netherlands.

[‖]Department Rehabilitation Science and Physiotherapy, Faculty of Medicine and Health Sciences, Ghent University, Ghent, Belgium.

[¶]High Performance Sport NZ, Sport Research Institute of New Zealand, Millennium Institute of Sport and Health, Mairangi Bay, Auckland, New Zealand.

The authors declared that they have no conflicts of interest in the authorship and publication of this contribution.

The American Journal of Sports Medicine, Vol. 44, No. 8
DOI: 10.1177/0363546516646086
© 2016 The Author(s)

Downloaded from ajs.sagepub.com at OHIO STATE UNIVERSITY LIBRARY on August 23, 2016

TABLE 1
Eligibility Criteria[a]

Inclusion Criteria	Exclusion Criteria
Index injury	
• Male athlete	• Reinjury ≤2 months
• Age 18-50 years	• Chronic hamstring complaints >2 months
• Acute onset of posterior thigh pain	• Grade 3 hamstring tear requiring surgery
• Clinical assessments and MRI ≤5 days from injury	• Contraindications to MRI
• MRI-confirmed grade 1 or 2 hamstring lesion	
• Available for follow-up	
Reinjury	
• Acute onset posterior thigh in the same leg as index injury ≤365 days since RTS after index injury	• MRI >10 days after onset of suspected reinjury
• MRI-confirmed hamstring reinjury	

MRI, magnetic resonance imaging; RTS, return to sport.

reported to occur most commonly in the biceps femoris muscle,[14,23,33,44] but the exact imaging-confirmed location within the muscle has only been evaluated in 2 small studies.[33,44] Silder[44] reported that the reinjuries occurred in generally the same location as the initial injury, and Koulouris et al[33] found that the musculotendinous junction within the muscle-tendon unit was the most common reinjury location, but no direct comparison between the index injury location and reinjury location was described. Although reinjuries are reported to occur within the first weeks after RTS,[5,36] increased susceptibility for reinjury seems to be present for several months after the initial injury.[12,22,35,36,51]

Thus far, the location and severity, in terms of the radiological extent, and the timing of MRI-confirmed reinjuries compared with MRI-confirmed index injuries have not been described. Therefore, the purposes of this descriptive study were to investigate the (1) location, (2) radiological severity, and (3) timing of reinjuries on MRI compared with the index injury.

METHODS

Study Design

This study was based on a prospective study investigating the predictive value of clinical and MRI examinations on RTS time after acute hamstring injuries using pooled data from a prospective case series and a randomized controlled trial.[24,53] The study was conducted at Aspetar Orthopaedic and Sports Medicine Hospital, a specialized sports medicine hospital in Qatar. For this descriptive substudy, we included all patients with MRI-confirmed reinjuries within 1 year after RTS. The study was approved by the ethics committees of Aspetar Orthopaedic and Sports Medicine Hospital and the Shafallah Medical Genetics Centre, and written informed consent was obtained from all participants.

Participants

Between January 2011 and June 2014, athletes with acute onset of posterior thigh pain were recruited consecutively from sporting clubs and federations in Qatar, mainly through the Qatar National Sports Medicine Program. Eligibility was assessed and determined in the outpatient department by the treating sports medicine physician. To be included in this study, athletes were required to meet the eligibility criteria presented in Table 1.

Index Injury

Within 5 days after injury, the treating sports medicine physician performed standardized comprehensive patient history taking and clinical examinations, including pain with hamstring range of motion testing, pain with manual muscle resistance testing, active slump test, and pain with palpation. We used the examination procedures as described in a previous study.[53]

MRI Protocol. With the athlete lying supine, images of the hamstring muscle were obtained from the ischial tuberosity to the knee using a 1.5-T magnet system (Magnetom Espree; Siemens) with a body matrix coil. We attached a vitamin E capsule to the athlete's posterior thigh corresponding with the point of maximal tenderness on palpation and confirmed with the athlete. Coronal and axial proton density–weighted images were first obtained (repetition time [TR]/echo time [TE], 3000/30 milliseconds; field of view [FOV], 220-240 mm; slice thickness, 3.5 mm; 333 × 512 matrix) with an echo train length (ETL) of 9 for the coronal images and 6 for the axial images. Subsequent coronal and axial fast-spin echo proton density–weighted fat-suppressed (PDw-FS) images were obtained (coronal images: TR/TE, 3000/32 milliseconds; FOV, 240 mm; slice thickness, 3.5 mm; 326 × 512 matrix; axial images: TR/TE, 3490/27 milliseconds; FOV, 320 mm; slice thickness, 3.5 mm; 333 × 512 matrix) with an ETL of 6. We considered a hamstring muscle injured if the MRI scan demonstrated increased signal intensity (ie, abnormal intramuscular increased signal compared with the adjacent unaffected muscle tissues) on fluid-sensitive sequences (PDw-FS). If >1 muscle was injured, the muscle with the greater extent of signal abnormality was defined as the "primary" injury.

MRI Assessments of Index Injury. A single experienced radiologist (E.A.) with >10 years of experience within

Downloaded from ajs.sagepub.com at OHIO STATE UNIVERSITY LIBRARY on August 23, 2016

musculoskeletal radiology assessed and scored the MRI scans and determined the localization and extent of the injury using a standardized scoring form based on the literature.[1,8,9,14,37,45] Good to excellent intra- and interobserver reliability were previously reported for these MRI measures in a study involving the same radiologist.[26] The radiologist was blinded to the clinical status of the injury and the RTS outcome. Assessment included measurements of the length (craniocaudal extent), width (mediolateral extent), and depth (anteroposterior extent) of increased signal intensity on the fluid-sensitive sequences (PDw-FS), as well as the distance from the most cranial pole of the injury to the ischial tuberosity (in centimeters) and the volume of the total edema, which was approximated using the formula for a prolate ellipsoid ([π/6] $\times$ anteroposterior $\times$ mediolateral $\times$ craniocaudal extent) (in cubic centimeters).[1,45] In addition, the location of involved muscle(s) was described, and an overall severity grading of the injury was scored using an MRI modification[14] of the Peetrons[37] classification (grade 0, no abnormalities; grade 1, edema without architectural distortion; grade 2, edema with architectural disruption; and grade 3, complete tear).

Treatment Received After Index Injury

Athletes included in the randomized controlled trial were randomized into 3 groups: 1 group received a platelet-rich plasma (PRP) injection, 1 group received a platelet-poor plasma (PPP) injection, and 1 group received no injection.[24] All 3 groups followed a 6-stage criteria-based rehabilitation program.[47] The study showed no benefit of PRP compared with no injection and a delayed RTS for PPP compared with PRP. The athletes included in the prospective case series received either the rehabilitation program as described above or individualized rehabilitation at the study center or in their club or federation.

Time to RTS After Index Injury

RTS was defined as the number of days from the initial injury until one of the physicians at the study center or the treating physician or physical therapist at the club or federation cleared the athlete to resume full unrestricted training. The RTS decision makers were not blinded to the baseline assessments or MRI findings.

For the athletes receiving rehabilitation at the study center, the treating physicians evaluated the athletes the same day that the athlete completed the final stage of the sports-specific functional field testing. The guidelines for RTS decisions included successful and asymptomatic completion of the progressive 6-phase criteria-based rehabilitation program, clinical evaluation, and interpretation of the results of isokinetic assessment.[47] For athletes receiving rehabilitation in the clubs or federations, we registered RTS once the athlete returned to full, unrestricted training. The number of days until registered RTS was provided by the club medical staff through weekly phone calls or e-mails.

Definition of Reinjury

Reinjury was defined as acute posterior thigh pain occurring during training or competition in the same leg as the index injury within 1 year after RTS from the index injury, confirmed by clinical evaluation and MRI showing increased signal intensity on fluid-sensitive sequences (PDw-FS).[15,17-19] We calculated the time (number of days) until reinjury in 2 ways: as the time from the index injury until reinjury and as the time from RTS after the index injury until reinjury.

Follow-up for Reinjury

In the randomized controlled trial, players were monitored monthly by telephone for reinjury (active follow-up). All athletes included were advised to contact the treating sports medicine physician if there was a clinical suspicion of reinjury. If this was confirmed by a clinical examination, an MRI examination was scheduled within 5 days after the onset of the suspected reinjury.

In the prospective case series, athletes were advised to contact the study center if there was a clinical suspicion of reinjury (passive follow-up). From September 2013, they were monitored by phone at 2 months, 6 months, and 1 year after RTS from the initial injury (active follow-up). If the clinical suspicion of reinjury was confirmed, the athlete was scheduled for MRI within 5 days after onset of the suspected reinjury.

MRI Assessments of Reinjury

MRI examinations were reviewed and scored by the same radiologist using the same scoring form as for the index injury, while he was blinded for the index injury scorings. In addition, the location of the reinjury and the presence of intramuscular scarring (fibrosis) were scored. To determine the location of the reinjury, axial and coronal views of the index injury and reinjury were directly compared on PDw-FS–weighted images and scored as (1) same muscle and same location within the muscle, (2) same muscle but other location within the muscle, and (3) different muscle. The reinjury was considered as being in the same location if the main signal abnormality was observed in the same region as before (ie, within the same anatomic location as described by Askling et al[1]; proximal tendon, proximal musculotendinous junction, proximal muscle belly, distal muscle belly, distal musculotendinous junction, or distal tendon) and within the same third (proximal, middle, third) of this anatomic location. The location of the injury was scored as the conjoint tendon if it affected the common tendon of the biceps femoris and semitendinosis.[50] The final decision was made by the radiologist through direct comparisons of the axial and coronal views. The severity of the reinjury was graded similarly as the index injury, using the MRI modification[14] of the Peetrons[37] classification. We defined an intramuscular scar as an area of abnormally low signal intensity in the intramuscular

Downloaded from ajs.sagepub.com at OHIO STATE UNIVERSITY LIBRARY on August 23, 2016

tissue compared with surrounding muscle tissue on all sequences (PDw and PDw-FS).[27,34,40] The presence or absence of an intramuscular scar was determined as the presence or absence of low signal intensity on the proton density–weighted images. Athletes receiving any injection therapy (PPP or PRP) had a follow-up MRI scan approximately 3 weeks after the index injury. These follow-up images were subsequently compared with the reinjury MRI scan to assess whether there was an increase in the extent of edema, which was interpreted as a result of the reinjury rather than residual signs of the injection

Statistical Analysis

We performed statistical analysis using SPSS software (version 21.0; IBM Corp). Continuous variables were tested for normality using the Kolmogorov-Smirnov test (where $P > .05$ was considered as normally distributed) and are presented as median values and interquartile ranges (IQRs). Descriptive data for categorical variables (ie, frequencies and proportions) are presented for subgroups, such as the type and number of muscles injured, injury location, and injury severity. The severity of the reinjury compared with the index injury was categorized based on the radiological grading, in which a less severe injury was graded lower and a more severe injury was graded higher than the index injury. Changes in injury characteristics between the index injury and reinjury for continuous data were analyzed using the Wilcoxon signed-rank test for nonparametric data (where $P < .05$ was considered statistically significant). Time after index injury and time after RTS after index injury are presented as the cumulative proportion (percentage) with reinjury.

RESULTS

Between January 2011 and June 2014, we included 180 athletes with a clinical diagnosis of acute hamstring injury available for follow-up for RTS (Figure 1). A total of 106 athletes were monitored systematically by phone (active follow-up). Ten of these athletes had a clinically suspected reinjury confirmed with MRI. Of the 74 athletes who were instructed to contact the study center but were not actively monitored by phone after RTS (passive follow-up), 10 sought medical assistance at the study center with posterior thigh pain in the same leg as the index injury within 1 year and had an MRI-confirmed reinjury within 10 days after injury. One athlete was excluded after imaging as a result of injury in muscle other than the hamstrings; therefore, 19 reinjuries in total were included in the analysis (Figure 1).

The athletes who sustained a reinjury were football (n = 18) or futsal (n = 1) players, with a mean (±SD) age of 26 ± 5 years, mean weight of 75 ± 8 kg, and mean height of 179 ± 7 cm. Five of the athletes with reinjuries received either a PRP (n = 2) or PPP (n = 3) injection within 5 days after the index injury.

The MRI characteristics for the index injury and reinjury are presented in Table 2. There were no significant differences in the MRI characteristics of the index injury or reinjury.

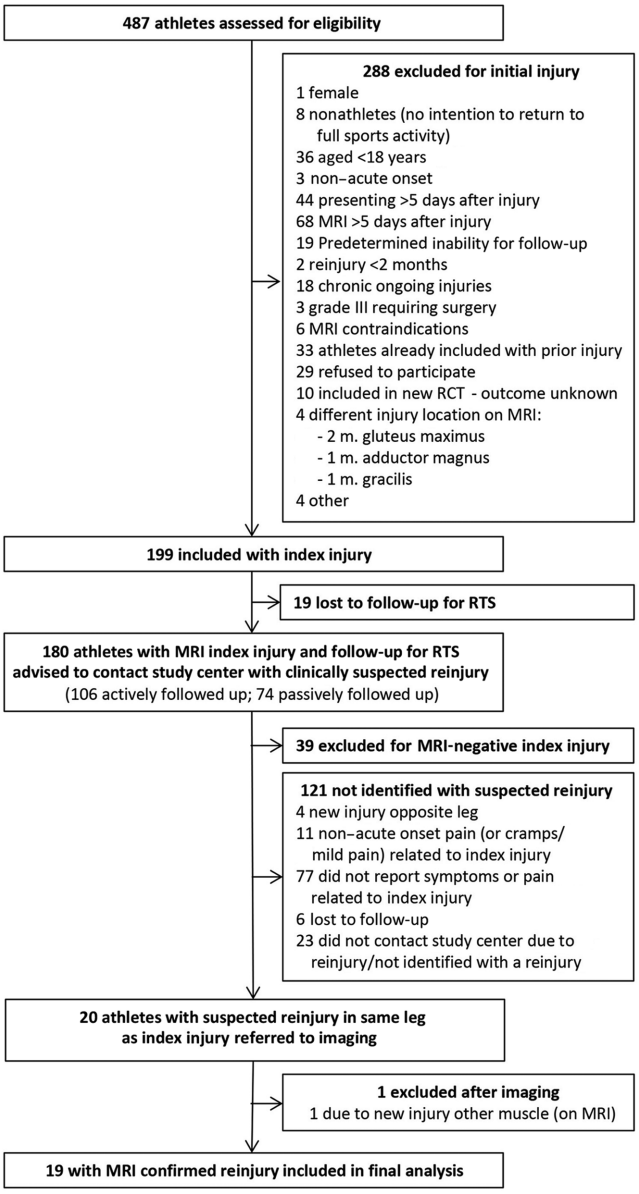

Figure 1. Study flow chart. MRI, magnetic resonance imaging; RCT, randomized controlled trial; RTS, return to sport.

Time to Reinjury

The median time to RTS after the index injury was 19 days (range, 5-37 days; IQR, 15 days). The median time between the index injury and reinjury was 60 days (range, 20-316; IQR, 131) and the median time between RTS after the index injury and the reinjury was 24 days (range, 4-311; IQR, 140). More than 50% of reinjuries occurred within the first 25 days (4 weeks) after RTS from the index injury (n = 10) and 70% of reinjuries occurred within 100 days (Figure 2). As shown in Figure 3, 50% of reinjuries

Downloaded from ajs.sagepub.com at OHIO STATE UNIVERSITY LIBRARY on August 23, 2016

TABLE 2
MRI Characteristics for the Index Injury and Reinjury[a]

	Index Injury	Reinjury
MRI measurements of increased signal intensity		
Distance ischial tuberosity, cm	10.4 (13.7)	12.2 (16.5)
Craniocaudal length, cm	11.9 (7.4)	11.5 (11.6)
Anteroposterior, cm	1.6 (1.4)	1.9 (1.2)
Mediolateral, cm	2.0 (1.8)	1.4 (1.5)
Volume, cm^3	26.8 (50.6)	18.8 (54.4)
Craniocaudal tear, cm[b]	1.0 (1.3)	1.4 (1.4)
Muscle injured		
BFlh	15/19 (78.9)	10/19 (52.6)
BFlh + ST	1/19 (5.3)	4/19 (21.1)
BFlh + BFsh	1/19 (5.3)	1/19 (5.3)
BFlh + SM	1/19 (5.3)	0/19 (0.0)
SM	1/19 (5.3)	3/19 (15.8)
ST	0/19 (0.0)	1/19 (5.3)
Anatomic location within the muscle		
Conjoint tendon	1/19 (5.3)	4/19 (21.1)
Proximal MTJ	12/19 (63.2)	9/19 (47.4)
Distal MTJ	5/19 (26.3)	4/19 (21.1)
Distal muscle belly	1/19 (5.3)	2/19 (10.5)
Number of muscles involved		
1 muscle	16/19 (84.2)	14/19 (73.7)
2 muscles	3/19 (15.8)	5/19 (26.3)
Severity: overall MRI grading		
Grade 1	11/19 (57.9)	10/19 (52.6)
Grade 2	8/19 (42.1)	7/19 (36.8)
Grade 3	0/19 (0.0)	2/19 (10.5)
Intramuscular fibrosis		
No fibrosis	—	11/19 (57.9)
Same location as index injury	—	7/19 (36.8)
Different location	—	1/19 (5.3)

[a]Data are expressed as median (interquartile range) or n/total (%). Dashes indicate not applicable. BFlh, long head of the biceps femoris; BFsh, short head of the biceps femoris; MRI, magnetic resonance imaging; MTJ, musculotendinous junction; SM, semimembranosus; ST, semitendinosus.

[b]Craniocaudal tear index injury (n = 8) and craniocaudal tear reinjury (n = 9).

occurred within 50 days after the index injury. In the first 6 weeks (42 days) after the index injury, all of the reinjuries occurred in the same location as the index injury (Figure 3). The athletes who received a PPP or PRP injection had a reinjury 20, 60, 71, 82, and 269 days after the index injury.

Location and Radiological Severity of Reinjuries

Table 3 presents the distribution of the reinjury location. The biceps femoris muscle was the most commonly injured muscle and was involved in 95% of index injuries (n = 18) and 79% of reinjuries (n = 15).

Of the 19 reinjuries, 79% occurred in the same muscle and same location within the muscle as the index injury (Figures 4 and 5; Table 3). The most common anatomic location within the muscle was the musculotendinous junction (n = 13; 68.4%), followed by the conjoint tendon (n = 4) and muscle belly (n = 2).

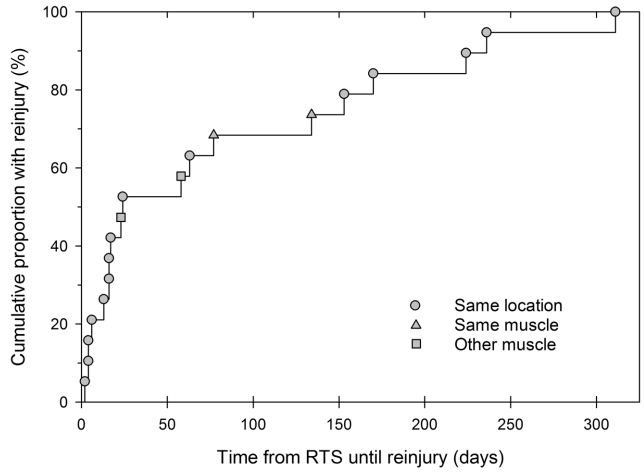

Figure 2. The cumulative proportion of the athletes with reinjuries and time between return to sport (RTS) after index injury and reinjury.

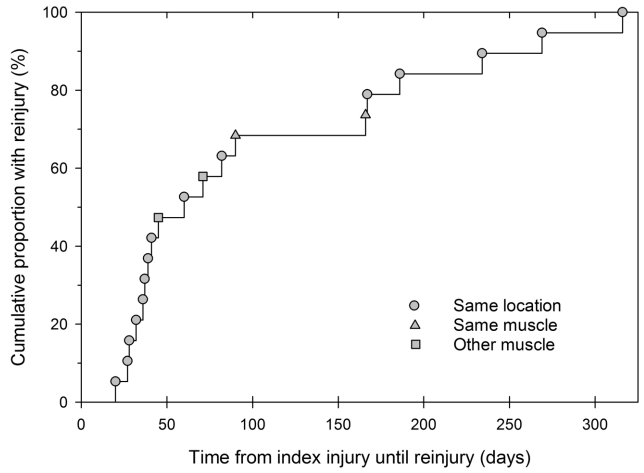

Figure 3. The cumulative proportion of the athletes with reinjuries and time between index injury and reinjury in days.

MRI severity grading revealed that 73.6% of reinjuries showed similar severity or were more severe than the index injury. Of the more severe reinjuries (37%), all occurred in the same location as the index injury. Two athletes with the index injury located in the long head of the biceps femoris had a complete rupture (grade 3) on reinjury: one located in the distal musculotendinous junction, also involving the short head of the biceps femoris, and one located in the proximal common tendon with a 15-mm separation.

Figure 6 illustrates that the reinjuries with more extensive craniocaudal length and greater extent of edema occurred earlier after the index injury.

Fibrosis

On reimaging, 8 athletes (42.1%) had intramuscular abnormal low signal intensity corresponding with fibrosis,

Downloaded from ajs.sagepub.com at OHIO STATE UNIVERSITY LIBRARY on August 23, 2016

TABLE 3
Radiological Severity and Location of the Reinjury[a]

	Same Muscle and Location	Same Muscle, Other Location	Different Muscle
Overall number	15 (79.0)	2 (10.5)	2 (10.5)
Muscle injured			
BFlh	9 (47.4)	1 (5.3)	0 (0.0)
BFlh + ST	4 (21.1)	0 (0.0)	0 (0.0)
BFlh + BFsh	1 (5.3)	0 (0.0)	0 (0.0)
SM	1 (5.3)	1 (5.3)	1 (5.3)
ST	0 (0.0)	0 (0.0)	1 (5.3)
Anatomic location within the muscle			
Conjoint tendon	4 (21.1)	—	—
Proximal MTJ	7 (36.8)	1 (5.3)	1 (5.3)
Distal MTJ	4 (21.1)	—	—
Distal muscle belly	—	1 (5.3)	1 (5.3)
Grading reinjury			
Grade 1	6 (31.6)	2 (10.5)	2 (10.5)
Grade 2	7 (36.8)	0 (0.0)	0 (0.0)
Grade 3	2 (10.5)	0 (0.0)	0 (0.0)
Severity reinjury vs index injury (radiological grading)			
Same grading	5 (26.3)	0 (0.0)	2 (10.5)
More severe	7 (36.8)	0 (0.0)	0 (0.0)
Less severe	3 (15.8)	2 (10.5)	0 (0.0)

[a]Data are expressed as the total number of all reinjuries (%). Dashes indicate not applicable. BFlh, long head of the biceps femoris; BFsh, short head of the biceps femoris; MTJ, musculotendinous junction; SM, semimembranosus; ST, semitendinosus.

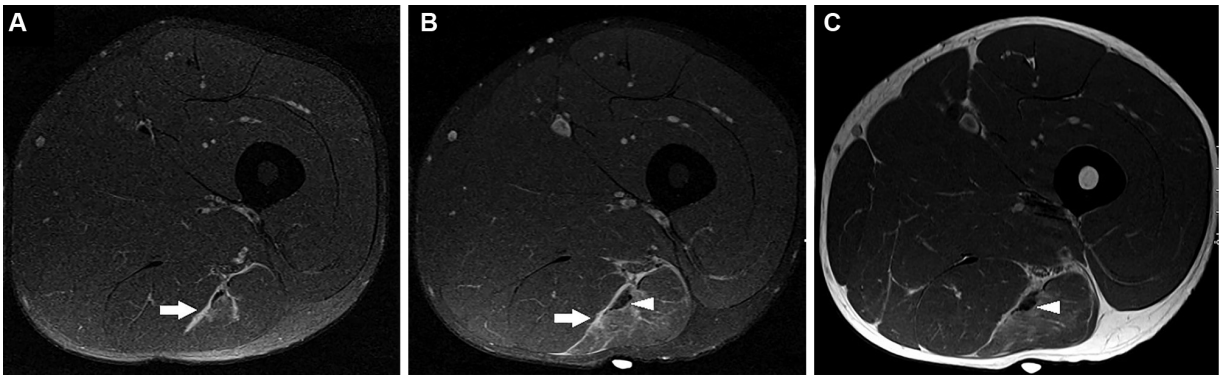

Figure 4. (A) A proton density–weighted fat-suppressed image of the index injury shows increased signal intensity at the proximal musculotendinous junction of the biceps femoris muscle (long head) (arrow). (B) A proton density–weighted fat-suppressed image of the reinjury shows increased signal intensity in the same location, with a greater extent of edema compared with the index injury. (C) The proton density–weighted images with (B) and without (C) fat suppression show an enlarged area of low signal intensity with thickening of the tendon, indicating fibrous tissue formation (arrowhead).

where in 7 of these, the fibrosis was located in the same site as the index injury (Figure 5).

DISCUSSION

This descriptive study shows that 79% of reinjuries within 1 year after acute hamstring injuries occurred in the same location. More than 50% of reinjuries occurred within 25 days (4 weeks) after RTS from the index injury and within 50 days after the index injury. All reinjuries within the first 6 weeks (42 days) after the index injury and all reinjuries that were more severe than the index injury in terms of radiological grading occurred in the same location as the index injury.

To our knowledge, this study is the first to provide a detailed description of MRI characteristics, in terms of location and severity, and timing of hamstring reinjuries compared with the index injury. Two studies previously reported reinjury imaging findings in smaller samples.[33,44] Although a direct comparison cannot be made, our findings are comparable with Silder,[44] who reported that the 3 reinjuries that were reimaged occurred in generally the same location as the initial injury, and injury severity was no worse than the initial injury.

Downloaded from ajs.sagepub.com at OHIO STATE UNIVERSITY LIBRARY on August 23, 2016

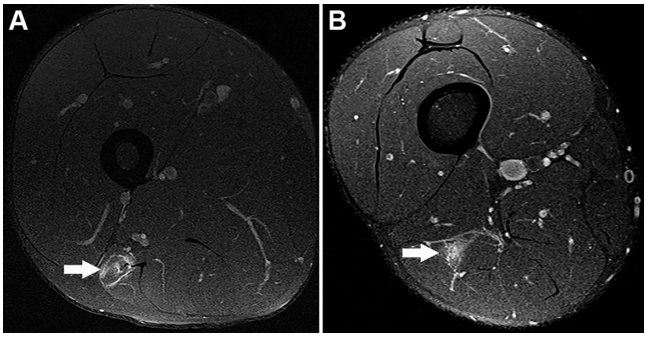

Figure 5. (A) A proton density–weighted fat-suppressed image of the index injury shows increased signal intensity at the proximal musculotendinous junction of the biceps femoris (long head) muscle (arrow). (B) A proton density–weighted fat-suppressed image of the reinjury shows increased signal intensity in a different location within the biceps femoris (long head) muscle, namely within the distal muscle belly (arrow).

The exact MRI location within the reinjured muscle compared with the index injury is poorly described.[44] An important finding in our study was that 79% of reinjuries occurred in the same location as the index injury, which may indicate incomplete healing. In accordance with previous findings,[14,23,33,44] the long head of the biceps femoris was the most commonly reinjured muscle. Ekstrand et al[14] found that all of the reinjuries registered among European professional football players occurred in the biceps femoris, and Hallén and Ekstrand[23] reported that the reinjury rate was higher in the biceps femoris (18%) compared with the semimembranosus and semitendinosus (2%). Askling et al[3,4] reported that reinjuries that occurred among football players,[4] sprinters, and jumpers[3] were all located in the long head of the biceps femoris. However, in these studies, a direct imaging-based comparison with the index injury was not described and the exact location within the muscle was not evaluated. Only Silder[44] reported that 3 reinjuries occurred in generally the same location, corresponding to the middle musculotendinous junction of the biceps femoris. Koulouris et al[33] found that 90% of reinjuries occurred in the biceps femoris compared with 80% of initial injuries. In our study, for the 2 injuries that occurred in a different muscle, both index injuries were located in the biceps femoris, whereas the reinjuries were located in the semimembranosus and semitendinosus, respectively. Given the small number of reinjuries, no conclusions can be drawn from these findings, but it is notable that the semitendinosus was more frequently involved together with the biceps femoris for the reinjuries. An explanation is that these reinjuries affected >1 muscle, where an index injury within the proximal musculotendinous junction also extended and affected the conjoint tendon and was more severe in terms of radiological grading. This is in agreement with Schuermans et al,[43] who suggested a neuromuscular alteration between the biceps femoris and semitendinosus, making them more susceptible to (re)injury.

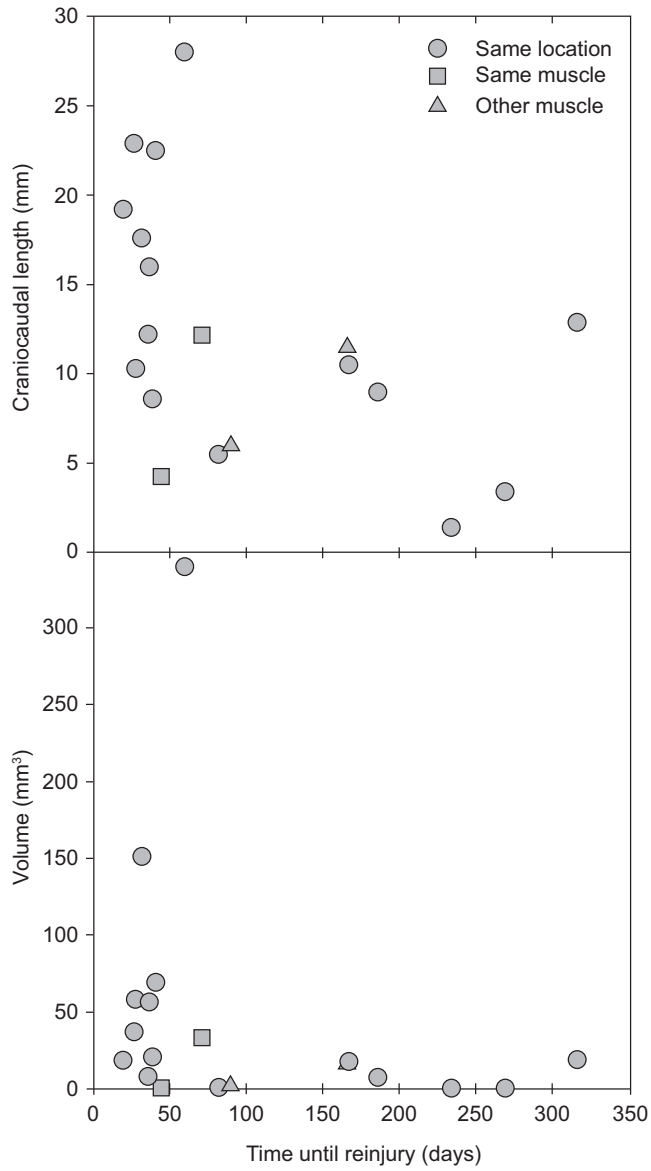

Figure 6. Association between the time from index injury until reinjury and the severity of reinjuries measured as the craniocaudal length of the edema and the volume of the edema.

It is frequently reported that reinjuries are associated with a longer period off from sports than index injuries.[5,6,13,28,33,52] However, Ekstrand et al[14] did not find any differences in RTS times between index hamstring injuries and reinjuries among professional football players. In our study, we found that 73.6% of reinjuries were either as severe as or more severe than the index injury in terms of radiological grading. We did not find any differences between the index injuries and reinjuries for the MRI measurements of injury extent. In contrast with Kouloris et al,[33] our study did not reveal any difference in the craniocaudal extent (of increased signal intensity) between the index injury and reinjury, although greater variance

Downloaded from ajs.sagepub.com at OHIO STATE UNIVERSITY LIBRARY on August 23, 2016

was seen in the MRI measurements for reinjuries in both studies. The most important finding, however, was that the radiologically more severe reinjuries (37%) occurred in the same location and earlier after RTS and the index injury.

An increased risk of reinjury has been reported within the first month after injury.[5,36] Brooks et al[5] reported that 59% of all reinjuries among English Rugby Union athletes occurred within 1 month. In European professional football players, 16% of hamstring injuries constituted reinjuries registered within 2 months after RTS.[14,23] Our findings are comparable, with more than one-half of reinjuries (10 of 19) occurring within the first 4 weeks and 70% occurring within the first 100 days after RTS.

Although most reinjuries occur early after the index injury and RTS, the risk of reinjury remains high for a substantially longer period compared with other injuries such as thigh contusions, medial collateral ligament sprains, and ankle sprains.[36] An elevated risk of reinjury within the same season[22,51] as well as the subsequent season[51] has been reported in Australian Rules football players. A prolonged time until reinjury from RTS is also reported in elite track and field athletes with clinical grades 1 to 4 injuries[35] and recreational athletes.[12] De Vos et al[12] reported a median of 100 days (range, 6-138 days) after RTS from index injury, with 41.2% (7 of 17) of reinjuries occurring within 2 months. In our study, despite the skewed distribution toward early occurrence, we found a wide variation in the number of days between RTS and reinjury, ranging from 4 to 311 days. In 5 of the 6 athletes sustaining a reinjury after 100 days, these also occurred in the same location as the index injury. This might reflect that biological healing of a skeletal muscle injury is incomplete or that muscle function (eg, eccentric strength) is not fully recovered even if the athlete is symptom free and has long since returned to full sports participation.

From this descriptive study, we cannot explain why there is a high incidence of early reinjuries and why these occur in the same location as the index injury. Healing of a muscle strain injury follows a complex process that includes well-coordinated steps of degeneration and inflammation, regeneration, and connective scar tissue formation (fibrosis),[21,29-32] in which time is a component that cannot be ignored. The duration of the biological healing process is unknown. It has been suggested that the immature scar tissue is the weak link[32] and incomplete healing and restoration of tensile strength is suggested to be associated with reinjury.[28,32,36,48] Fyfe et al[20] suggested in a conceptual framework that maladaptations (eg, eccentric hamstring weakness, selective hamstring atrophy, and shifts in the torque joint angle relationship, especially at longer muscle lengths) might develop after a hamstring injury as a result of prolonged neuromuscular inhibition if not adequately addressed during rehabilitation. Architectural asymmetries, such as shorter fascicle lengths and greater pennation angle in the long head of the biceps femoris,[46] might also play a role in the origin of hamstring reinjuries, although further research is needed in this area.

In our study, we defined a reinjury as the acute onset of posterior thigh pain in the same leg as index injury $\leq$365 days since RTS after the index injury, confirmed with MRI. Although different definitions of a hamstring reinjury are used in the literature and debated,[15] our definition regarding the location is in accordance with a previous recommendation.[11,17,18] It seems likely that a reinjury in the same location as the index injury is related to the index injury. However, the degree to which a reinjury in a different location within the muscle or in a different muscle is related to the index injury remains unknown.

The clinical relevance of our findings lies first in how we approach the management of the index injury, not only during rehabilitation and in the RTS decision-making process but also after RTS. Our findings indicate that the injury is not completely healed, which may explain why the majority of the athletes sustained a reinjury at the same location as the index injury and early after RTS. Protocols for optimal loading after RTS from the index injury are needed, focusing on secondary and tertiary prevention. First, individuals must continue to perform specific hamstring exercises after RTS; the rehabilitation stage (before RTS) should directly continue into a prevention stage (after RTS). High-level evidence shows that the 10-week Nordic hamstring exercise program reduces the risk of reinjury by as much as 86%.[38,49] Second, our findings indicate that time is a factor that clinicians and athletes should be acutely aware of when balancing benefits and harms in the RTS process, especially at the elite level. Unfortunately, no objective validated RTS criteria exist. This area is a priority for future research.

Strengths

This is the first study to investigate the radiological severity, location, and timing of MRI-confirmed reinjuries compared with index injuries. Strengths include the standardized clinical and MRI examination procedures and the single-study center design, which increase the internal validity of the study.

Limitations

One of the limitations of our study is that although the guidelines for RTS at the study center were well defined, the criteria for RTS in the clubs or federations were dependent of the treating club physiotherapist or physician and therefore probably varied.

Regarding timing, we included athletes with a reinjury within 1 year after RTS, but it may be argued that this time limit is artificial. The number of included athletes with a reinjury was relatively small, although this is the largest study to date. To obtain larger samples, multicenter studies might be more appropriate.

Because we obtained the MRI measurements based on 2-dimensional images using a 1.5-T scanner, we do not know whether using more advanced MRI techniques and software[10,16] or a 3.0-T scanner would have provided more accurate information. We used a simple categorical grading system based on severity, which is widely used in clinical practice as well as in research.[14,25,37] It might be that more comprehensive classification systems also emphasizing the location of injury within the muscle[7,39]

Downloaded from ajs.sagepub.com at OHIO STATE UNIVERSITY LIBRARY on August 23, 2016

would have provided more detailed information about the location of the injury. However, we considered a direct comparison between the index and reinjury MRI images as the most accurate method for assessing the exact location of the reinjury, although the reproducibility of this comparison was not formally assessed.

Although the athletes were clinically diagnosed with a reinjury, we cannot ensure that the presence of increased signal intensity of MRI of the reinjury represented healing of the index injury or a real reinjury. The presence of intramuscular increased signal intensity on MRI might persist for a prolonged time[1,2,9,41,42,44] and may even increase after clinical recovery.[1,9] It is therefore likely that the MRI findings of the reinjuries in the same location reflect an overlap of the index injury and the reinjury.

Finally, we could not provide information about the days to RTS of the reinjury as a result of incomplete follow-up. Thus, the results reflect only the radiological severity of the reinjuries, and future studies should preferably report on both radiological findings and clinical outcome (time to RTS) after hamstring reinjuries to provide more accurate information about severity when comparing index injuries with reinjuries. Because we did not have active reinjury registration for all of the athletes with an index injury, there might have been reinjuries that we were not able to identify.

CONCLUSION

The majority of hamstring reinjuries in this study occurred in the same location as the index injury, and these reinjuries happened relatively early after RTS and with a radiological greater extent. Our findings suggest that although the athletes were clinically recovered after their index injury and were cleared for RTS, biological and/or functional healing of the index injury might not be fully completed, leading to a reinjury at the index injury site. Specific exercise programs focusing on reinjury prevention initiated after RTS from the index injury are therefore highly recommended.

ACKNOWLEDGMENT

The authors thank the Sports Medicine Physicians and the staff of the Outpatient Department, Radiology Department, Rehabilitation Department, and Orthopaedic Department at Aspetar Orthopaedic and Sports Medicine Hospital and the staff of the Qatar National Sports Medicine Program for contributions to this study. The authors also extend thanks to Sirine Boukarroum for work on the data collection.

REFERENCES

1. Askling CM, Tengvar M, Saartok T, Thorstensson A. Acute first-time hamstring strains during high-speed running: a longitudinal study including clinical and magnetic resonance imaging findings. *Am J Sports Med*. 2007;35(2):197-206.
2. Askling CM, Tengvar M, Saartok T, Thorstensson A. Acute first-time hamstring strains during slow-speed stretching: clinical, magnetic resonance imaging, and recovery characteristics. *Am J Sports Med*. 2007;35(10):1716-1724.
3. Askling CM, Tengvar M, Tarassova O, Thorstensson A. Acute hamstring injuries in Swedish elite sprinters and jumpers: a prospective randomised controlled clinical trial comparing two rehabilitation protocols. *Br J Sports Med*. 2014;48(7):532-539.
4. Askling CM, Tengvar M, Thorstensson A. Acute hamstring injuries in Swedish elite football: a prospective randomised controlled clinical trial comparing two rehabilitation protocols. *Br J Sports Med*. 2013;47(15):953-959.
5. Brooks JHM, Fuller CW, Kemp SPT, Reddin DB. Incidence, risk, and prevention of hamstring muscle injuries in professional rugby union. *Am J Sports Med*. 2006;34(8):1297-1306.
6. Brooks JHM, Fuller CW, Kemp SPT, Reddin DB. Epidemiology of injuries in English professional rugby union: part 2 training injuries. *Br J Sports Med*. 2005;39(10):767-775.
7. Chan O, Del Buono A, Best TM, Maffulli N. Acute muscle strain injuries: a proposed new classification system. *Knee Surg Sports Traumatol Arthrosc*. 2012;20(11):2356-2362.
8. Comin J, Malliaras P, Baquie P, Barbour T, Connell D. Return to competitive play after hamstring injuries involving disruption of the central tendon. *Am J Sports Med*. 2012;41(1):111-115.
9. Connell DA, Schneider-Kolsky ME, Hoving JL, et al. Longitudinal study comparing sonographic and MRI assessments of acute and healing hamstring injuries. *AJR Am J Roentgenol*. 2004;183(4):975-984.
10. Crema MD, Yamada AF, Guermazi A, Roemer FW, Skaf AY. Imaging techniques for muscle injury in sports medicine and clinical relevance. *Curr Rev Musculoskelet Med*. 2015;8(2):154-161.
11. de Visser HM, Reijman M, Heijboer MP, Bos PK. Risk factors of recurrent hamstring injuries: a systematic review. *Br J Sports Med*. 2012;46(2):124-130.
12. De Vos RJ, Reurink G, Goudswaard GJ, Moen MH, Weir A, Tol JL. Clinical findings just after return to play predict hamstring re-injury, but baseline MRI findings do not. *Br J Sports Med*. 2014;48(18):1377-1384.
13. Ekstrand J, Hagglund M, Walden M. Epidemiology of muscle injuries in professional football (soccer). *Am J Sports Med*. 2011;39(6):1226-1232.
14. Ekstrand J, Healy JC, Waldén M, Lee JC, English B, Hägglund M. Hamstring muscle injuries in professional football: the correlation of MRI findings with return to play. *Br J Sports Med*. 2012;46(2):112-117.
15. Finch CF, Cook J. Categorising sports injuries in epidemiological studies: the subsequent injury categorisation (SIC) model to address multiple, recurrent and exacerbation of injuries. *Br J Sports Med*. 2014;48(17):1276-1280.
16. Froeling M, Oudeman J, Strijkers GJ, et al. Muscle changes detected with diffusion-tensor imaging after long-distance running. *Radiology*. 2015;274(2):548-562.
17. Fuller CW. Consensus statement on injury definitions and data collection procedures in studies of football (soccer) injuries. *Br J Sports Med*. 2006;40(3):193-201.
18. Fuller CW, Bahr R, Dick RW, Meeuwisse WH. A framework for recording recurrences, reinjuries, and exacerbations in injury surveillance. *Clin J Sport Med*. 2007;17(3):197-200.
19. Fuller CW, Molloy MG, Bagate C, et al. Consensus statement on injury definitions and data collection procedures for studies of injuries in rugby union. *Clin J Sport Med*. 2007;17(3):177-181.
20. Fyfe JJ, Opar DA, Williams MD, Shield AJ. The role of neuromuscular inhibition in hamstring strain injury recurrence. *J Electromyogr Kinesiol*. 2013;23(3):523-530.
21. Gharaibeh B, Chun-Lansinger Y, Hagen T, et al. Biological approaches to improve skeletal muscle healing after injury and disease. *Birth Defects Res Part C Embryo Today Rev*. 2012;96(1):82-94.
22. Gibbs NJ, Cross TM, Cameron M, Houang MT. The accuracy of MRI in predicting recovery and recurrence of acute grade one hamstring muscle strains within the same season in Australian Rules football players. *J Sci Med Sport*. 2004;7(2):248-258.

Downloaded from ajs.sagepub.com at OHIO STATE UNIVERSITY LIBRARY on August 23, 2016

23. Hallén A, Ekstrand J. Return to play following muscle injuries in professional footballers. *J Sports Sci*. 2014;32(13):1229-1236.
24. Hamilton B, Tol JL, Almusa E, et al. Platelet-rich plasma does not enhance return to play in hamstring injuries: a randomised controlled trial. *Br J Sports Med*. 2015;49(14):943-950.
25. Hamilton B, Valle X, Rodas G, et al. Classification and grading of muscle injuries: a narrative review. *Br J Sports Med*. 2015;49(5):306.
26. Hamilton B, Whiteley R, Almusa E, Roger B, Geertsema C, Tol JL. Excellent reliability for MRI grading and prognostic parameters in acute hamstring injuries. *Br J Sports Med*. 2014;48(18):1385-1387.
27. Hayashi D, Hamilton B, Guermazi A, de Villiers R, Crema MD, Roemer FW. Traumatic injuries of thigh and calf muscles in athletes: role and clinical relevance of MR imaging and ultrasound. *Insights Imaging*. 2012;3(6):591-601.
28. Heiderscheit BC. Hamstring strain injuries: recommendations for diagnosis, rehabilitation, and injury prevention. *J Orthop Sports Phys Ther*. 2010;40(2):67-81.
29. Huard J, Li Y, Fu FH. Muscle injuries and repair: current trends in research. *J Bone Joint Surg Am*. 2002;84(5):822-832.
30. Hurme T, Kalimo H, Lehto M, Järvinen M. Healing of skeletal muscle injury: an ultrastructural and immunohistochemical study. *Med Sci Sports Exerc*. 1991;23(7):801-810.
31. Järvinen TA, Järvinen M, Kalimo H. Regeneration of injured skeletal muscle after the injury. *Muscles Ligaments Tendons J*. 2013;3(4):337-345.
32. Järvinen TA, Järvinen TL, Kääriäinen M, Kalimo H, Järvinen M. Muscle injuries: biology and treatment. *Am J Sports Med*. 2005;33(5):745-764.
33. Koulouris G, Connell DA, Brukner P, Schneider-Kolsky M. Magnetic resonance imaging parameters for assessing risk of recurrent hamstring injuries in elite athletes. *Am J Sports Med*. 2007;35(9):1500-1506.
34. Lee JC, Mitchell AWM, Healy JC. Imaging of muscle injury in the elite athlete. *Br J Radiol*. 2012;85(1016):1173-1185.
35. Malliaropoulos N, Isinkaye T, Tsitas K, Maffulli N. Reinjury after acute posterior thigh muscle injuries in elite track and field athletes. *Am J Sports Med*. 2011;39(2):304-310.
36. Orchard J, Best TM. The management of muscle strain injuries: an early return versus the risk of recurrence. *Clin J Sport Med*. 2002;12(1):3-5.
37. Peetrons P. Ultrasound of muscles. *Eur Radiol*. 2002;12(1):35-43.
38. Petersen J, Thorborg K, Nielsen MB, Budtz-Jorgensen E, Holmich P. Preventive effect of eccentric training on acute hamstring injuries in men's soccer: a cluster-randomized controlled trial. *Am J Sports Med*. 2011;39(11):2296-2303.
39. Pollock N, James SLJ, Lee JC, Chakraverty R. British athletics muscle injury classification: a new grading system. *Br J Sports Med*. 2014;48(18):1347-1351.
40. Reurink G, Almusa E, Goudswaard GJ, et al. No association between fibrosis on magnetic resonance imaging at return to play and hamstring reinjury risk. *Am J Sports Med*. 2015;43(5):1228-1234.
41. Reurink G, Goudswaard GJ, Tol JL, et al. MRI observations at return to play of clinically recovered hamstring injuries. *Br J Sports Med*. 2014;48(18):1370-1376.
42. Sanfilippo JL, Silder A, Sherry MA, Tuite MJ, Heiderscheit BC. Hamstring strength and morphology progression after return to sport from injury. *Med Sci Sports Exerc*. 2013;45(3):448-454.
43. Schuermans J, Van Tiggelen D, Danneels L, Witvrouw E. Biceps femoris and semitendinosus–teammates or competitors? New insights into hamstring injury mechanisms in male football players: a muscle functional MRI study. *Br J Sports Med*. 2014;48(22):1599-1606.
44. Silder A. Clinical and morphological changes following 2 rehabilitation programs for acute hamstring strain injuries: a randomized clinical trial. *J Orthop Sports Phys Ther*. 2013;43(5):284-299.
45. Slavotinek JP, Verrall GM, Fon GT. Hamstring injury in athletes: using MR imaging measurements to compare extent of muscle injury with amount of time lost from competition. *AJR Am J Roentgenol*. 2002;179(6):1621-1628.
46. Timmins RG, Shield AJ, Williams MD, Lorenzen C, Opar DA. Biceps femoris long head architecture: a reliability and retrospective injury study. *Med Sci Sports Exerc*. 2015;47(5):905-913.
47. Tol JL, Hamilton B, Eirale C, Muxart P, Jacobsen P, Whiteley R. At return to play following hamstring injury the majority of professional football players have residual isokinetic deficits. *Br J Sports Med*. 2014;48(18):1364-1369.
48. Ueblacker P, Mueller-Wohlfahrt HW, Ekstrand J. Epidemiological and clinical outcome comparison of indirect (''strain'') versus direct (''contusion'') anterior and posterior thigh muscle injuries in male elite football players: UEFA Elite League study of 2287 thigh injuries (2001–2013). *Br J Sports Med*. 2015;49(22):1461-1465.
49. van der Horst N, Smits DW, Petersen J, Goedhart EA, Backx FJG. The preventive effect of the Nordic hamstring exercise on hamstring injuries in amateur soccer players: a randomized controlled trial. *Am J Sports Med*. 2015;43(6):1316-1323.
50. van der Made AD, Reurink G, Gouttebarge V, Tol JL, Kerkhoffs GM. Outcome after surgical repair of proximal hamstring avulsions: a systematic review. *Am J Sports Med*. 2015;43(11):2841-2851.
51. Verrall GM, Slavotinek JP, Barnes PG, Fon GT, Esterman A. Assessment of physical examination and magnetic resonance imaging findings of hamstring injury as predictors for recurrent injury. *J Orthop Sports Phys Ther*. 2006;36(4):215-224.
52. Walden M, Hagglund M, Ekstrand J. Injuries in Swedish elite football–a prospective study on injury definitions, risk for injury and injury pattern during 2001. *Scand J Med Sci Sports*. 2005;15(2):118-125.
53. Wangensteen A, Almusa E, Boukarroum S, et al. MRI does not add value over and above patient history and clinical examination in predicting time to return to sport (RTS) after acute hamstring injuries: a prospective cohort of 180 male athletes. *Br J Sports Med*. 2015;49(4):1579-1587.

For reprints and permission queries, please visit SAGE's Web site at http://www.sagepub.com/journalsPermissions.nav.

Downloaded from ajs.sagepub.com at OHIO STATE UNIVERSITY LIBRARY on August 23, 2016